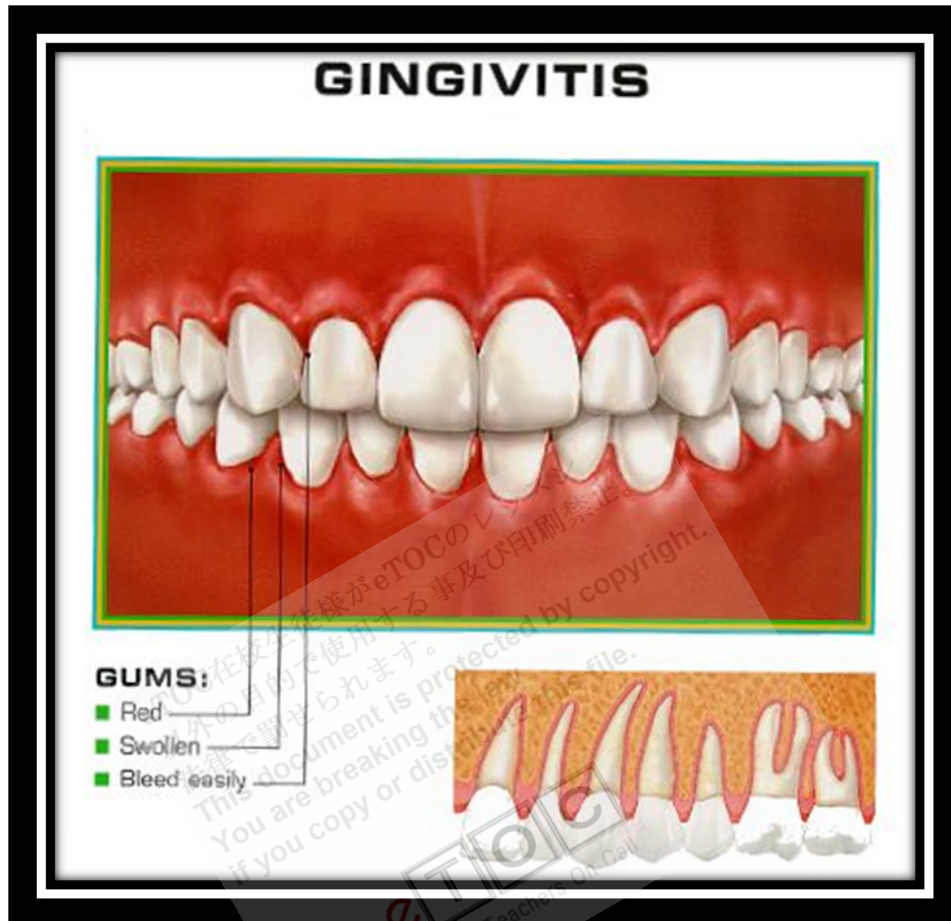

Gingivitis



<http://www.benjaminwyong.com/wp-content/uploads/2011/06/gingiv1.jpg>

*Gingivitis is inflammation of the **gingivae**, causing bleeding with swelling, redness, **exudate**, a change of normal contours, and, occasionally, discomfort. Diagnosis is based on inspection. Treatment involves professional teeth cleaning and intensified home dental hygiene. Advanced cases may require antibiotics or surgery.*

Normally, the gingivae are firm, tightly adapted to the teeth, and contoured to a point. **Keratinized gingiva** near the crowns is pink stippled tissue. This tissue should fill the entire space between the crowns. The gingiva farther from the crowns, called alveolar mucosa, is **nonkeratinized**, highly **vascular**, red, movable, and continuous with the **buccal mucosa**. A tongue depressor should express no blood or pus from normal gingiva.

Inflammation, or gingivitis, the most common gingival problem, may evolve into [periodontitis](#).

Etiology

The most common cause of gingivitis is poor oral hygiene.

Poor oral hygiene allows plaque to accumulate between the gingiva and the teeth; gingivitis does not occur in places where teeth are missing. Irritation due to plaque deepens the normal crevice ([sulcus](#)) between the tooth and gingiva, creating gingival pockets. These pockets contain bacteria that may cause gingivitis and root caries. Other local factors, such as malocclusion, dental calculus, food impaction, faulty dental restorations, and [xerostomia](#), play a secondary role.

Systemic causes: Gingivitis also commonly occurs at puberty, during menstruation and pregnancy, and at menopause, presumably because of hormonal changes. Similarly, oral (or injectable) contraceptives may exacerbate inflammation.

Gingivitis may be an early sign of a systemic disorder, especially those that affect the response to infection (eg, diabetes, AIDS, vitamin deficiency, [leukopenia](#)), particularly if it occurs in patients with minimal dental plaque. Some patients with [Crohn's disease](#) have a cobblestone area of [granulomatous gingival hypertrophy](#) when intestinal flare-ups occur. Exposure to heavy metals (eg, [lead](#), [bismuth](#)) may cause gingivitis and a dark line at the gingival margin. Severe deficiency of [niacin](#) ([pellagra](#)) or vitamin C ([scurvy](#)) can cause gingivitis; these deficiencies are rare in the US.

Symptoms and Signs

Simple gingivitis first causes a deepening of the [sulcus](#) between the tooth and gingiva, followed by a band of red, inflamed gingiva along one or more teeth, with swelling of the interdental papillae and easily induced bleeding. Pain is usually absent. The inflammation may resolve, remain superficial for years, or occasionally progress to periodontitis.

[Pericoronitis](#) is acute, painful inflammation of the [gingival flap](#) ([operculum](#)) over a partly erupted tooth, usually around [mandibular 3rd molars](#) ([wisdom teeth](#)). Infection is common, and an [abscess](#) or [cellulitis](#) may develop. Pericoronitis often recurs as food gets trapped beneath the flap. The gingival

flap disappears when the tooth is fully erupted. Many wisdom teeth do not erupt and are termed impacted.

Desquamative gingivitis may occur during menopause. It is characterized by deep red, painful gingival tissue that bleeds easily. **Vesicles** may precede **desquamation**. The gingivae are soft because the keratinized cells that resist abrasion by food particles are absent. A similar gingival lesion may be associated with **pemphigus vulgaris**, **bullous pemphigoid**, **benign mucous membrane pemphigoid**, or **atrophic lichen planus**.

During pregnancy, swelling, especially of the **interdental papillae**, is likely to occur. Soft, reddish **pedunculated gingival growths** often arise in the interdental papillae during the 1st trimester, may persist throughout pregnancy, and may or may not subside after delivery. Such growths are pyogenic granulomas that are sometimes referred to as pregnancy tumors. They develop rapidly and then remain static. An underlying irritant is common, such as calculus or a restoration with a rough margin. These growths also may occur in nonpregnant women and men.

Uncontrolled diabetes can exaggerate the effects of gingival irritants, making secondary infections and acute gingival abscesses common.

In leukemia, the gingivae may become engorged with a leukemic infiltrate, exhibiting clinical symptoms of edema, pain, and easily induced bleeding.

In scurvy, the gingivae are inflamed, **hyperplastic**, and **engorged**, bleeding easily. **Petechiae** and **ecchymoses** may appear throughout the mouth.

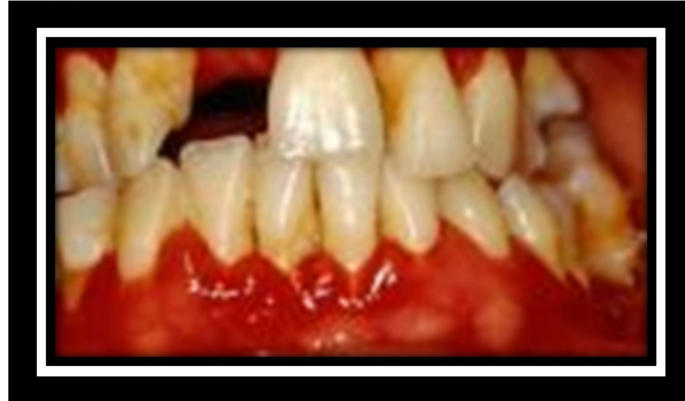In **pellagra**, the gingivae are inflamed, bleed easily, and are susceptible to secondary infection. Additionally, the lips are reddened and cracked, the mouth feels scalded, the tongue is smooth and bright red, and the tongue and **mucosa** may have **ulcerations**.

Diagnosis

- Clinical evaluation

Finding **erythematous**, friable tissue at the gum lines confirms the diagnosis. To detect early gingival disease, some dentists frequently measure the depth of the pocket around each tooth. Depths < 3 mm are normal; deeper pockets are at high risk of **gingivitis** and **periodontitis**.

Gingivitis



Treatment

- Regular oral hygiene and professional cleaning

Simple gingivitis is controlled by proper oral hygiene with or without an antibacterial mouth rinse. Thorough scaling (professional cleaning with hand or **ultrasonic instruments**) should be done. If appropriate, poorly contoured restorations are reshaped or replaced and local irritants are removed. Excess gingiva, if present, can be excised. Drugs causing **gingival hyperplasia** should be stopped if possible; if not, improved home care and more frequent professional cleanings (at least every 3 mo) usually reduce the hyperplasia. Pregnancy tumors are excised.

Pericoronitis treatment consists of

- Removal of debris from under the gingival flap
- Rinses with saline, 1.5% **hydrogen peroxide**, or 0.12% **chlorhexidine**
- Extraction (particularly when episodes recur)

If severe infection develops, antibiotics may be given for a day before extraction and continued during healing. A common regimen is amoxicillin 500 mg po q 6 h for 10 days (or until 3 days after all inflammation has subsided). Abscesses associated with **pericoronitis** require localized incision and drainage, a periodontal flap and root debridement, or extraction.

In gingivitis caused by systemic disorders, treatment is directed at the cause. In **desquamative gingivitis** during menopause, sequential administration of estrogens

and **progestins** may be beneficial, but adverse effects of this therapy limit recommendations for its use. Otherwise, dentists may prescribe a **corticosteroid rinse** or a **corticosteroid paste** that is applied directly to the gums. Gingivitis caused by **pemphigus vulgaris** and similar **muco-cutaneous** conditions may require systemic **corticosteroid therapy**.

Prevention

Daily removal of plaque with dental floss and a toothbrush and routine cleaning by a dentist or hygienist at 6-mo to 1-yr intervals can help minimize gingivitis. Patients with systemic disorders predisposing to gingivitis require more frequent professional cleanings (from every 2 wk to every 3 mo).

Key Points

- Gingivitis is caused mainly by poor oral hygiene but is sometimes due to hormonal changes (eg, pregnancy, menopause) or certain systemic disorders (eg, diabetes, AIDS).
- Professional cleaning with or without an antibacterial rinse is usually adequate treatment.
- Systemic causes must also be treated.

ACUTE NECROTIZING ULCERATIVE GINGIVITIS (ANUG)

(Fusospirochetosis; Trench Mouth; Vincent's Infection or Angina)

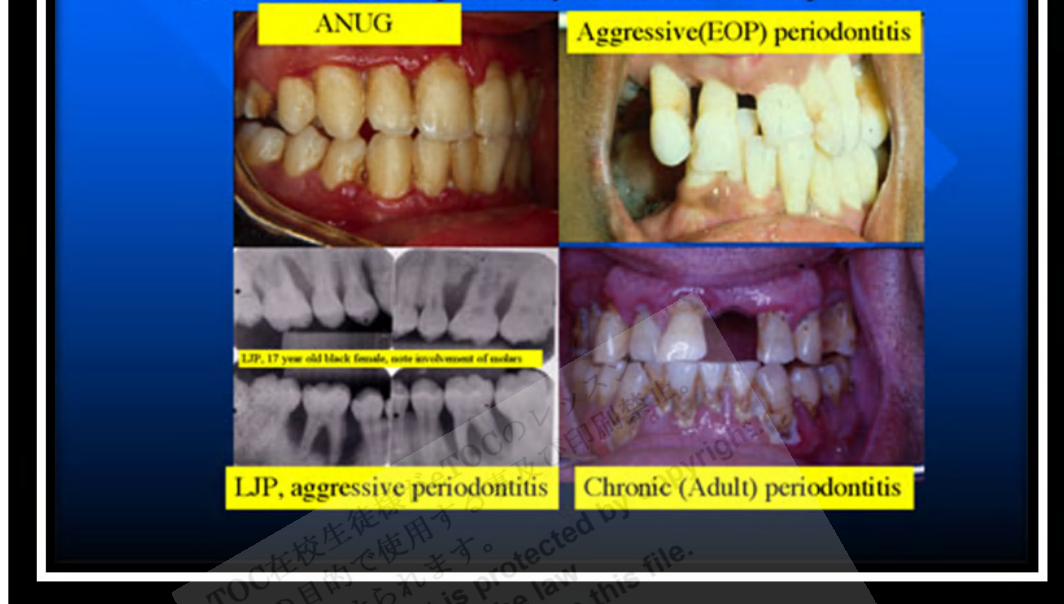
Acute necrotizing ulcerative gingivitis is a painful infection of the gums. Symptoms are acute pain, bleeding, and foul breath. Diagnosis is based on clinical findings. Treatment is gentle debridement, improved oral hygiene, mouth rinses, supportive care, and, if debridement must be delayed, antibiotics.

Acute necrotizing ulcerative gingivitis (ANUG) occurs most frequently in smokers and debilitated patients who are under stress. Other risk factors are poor oral hygiene, nutritional deficiencies, and sleep deprivation.

Symptoms and Signs

The usually abrupt onset may be accompanied by malaise or fever. The chief manifestations are acutely painful, bleeding **gingivae**; excessive salivation; and overwhelmingly foul breath (**fetor oris**). **Ulcerations**, which are **pathognomonic**, are present on the **dental papillae** and **marginal gingiva**. These ulcerations have a characteristically punched-out appearance and are

The Bacterial Flora in all Forms of Periodontal Disease Reflects the Overgrowth of Certain Anaerobes, especially the BANA Species



<http://www.dent.umich.edu/media/research/loeschelabs/eduantimicrobial.html>

covered by a gray **pseudomembrane**. Similar lesions on the **buccal mucosa** and tonsils are rare. Swallowing and talking may be painful. Regional lymphadenopathy often is present.

Diagnosis

- Clinical evaluation

Rarely, **tonsillar** or **pharyngeal tissues** are affected, and **diphtheria** or infection due to **agranulocytosis** must be ruled out by throat culture and CBC when the gum manifestations do not respond quickly to conventional therapy.

Treatment

- Debridement
- Rinses (eg, **hydrogen peroxide**, **chlorhexidine**)
- Improved oral hygiene
- Sometimes oral antibiotics

Treatment consists of gentle debridement with a **hand scaler** or **ultrasonic device**. Debridement is done over several days. The patient uses a soft

toothbrush or washcloth to wipe the teeth. Rinses at hourly intervals with warm normal **saline** or twice/day with 1.5% **hydrogen peroxide** or 0.12% **chlorhexidine** may help during the first few days after initial **debridement**. Essential supportive measures include improving oral hygiene (done gently at first), adequate nutrition, high fluid intake, rest, **analgesics** as needed, and avoiding irritation (eg, caused by smoking or hot or spicy foods). Marked improvement usually occurs within 24 to 48 h, after which debridement can be completed. If debridement is delayed (eg, if a dentist or the instruments necessary for debridement are unavailable), oral antibiotics (eg, **amoxicillin** 500 mg q 8 h, **erythromycin** 250 mg q 6 h, or **tetracycline** 250 mg q 6 h) provide rapid relief and can be continued until 72 h after symptoms resolve. If the gingival contour inverts (ie, if the tips of papillae are lost) during the acute phase, surgery is eventually required to prevent subsequent periodontitis.

Reference: <http://www.merckmanuals.com>

eTOC在校生がeTOCのレッスン
以外の目的で使用することは法律で罰せられます。
This document is protected by copyright.
You are breaking the law
if you copy or distribute this file.

eTOC
English Teachers On Call